

## Percutaneous Management of Benign Biliary Strictures

*Anthony C. Venbrux, M.D., and Floyd A. Osterman, Jr., M.D.*

### ABSTRACT

The interventional radiologist plays an increasing role in the management of patients with benign biliary disease. This article summarizes the percutaneous management of patients with benign biliary strictures and includes a discussion of currently available techniques. The techniques of percutaneous transhepatic cholangiography and biliary drainage will be reviewed. This includes anatomic and technical considerations of the right mid-axillary and left subxyphoid percutaneous approaches, a review of percutaneous dilation of biliary strictures, and the management of patients with chronic indwelling biliary drainage catheters (i.e., periodic catheter exchanges, catheter flushing, etc). The article concludes with a discussion of biliary drainage catheters and the clinical and physiological parameters used in making a decision to remove the tube.

The patient presenting with clinical signs and symptoms of obstructive jaundice requires a multidisciplinary approach for effective clinical management. The interventional radiologist plays an increasing role through advanced diagnostic imaging, precisely defining bile duct anatomy (percutaneous transhepatic cholangiography), providing access into the biliary system (percutaneous biliary drainage), and offering a number of therapeutic options including percutaneous management of biliary strictures using catheter, guidewire, balloon, and stent technology. Supplementing the percutaneous techniques mentioned above is the recent application by radiologists of percutaneous biliary endoscopy performed through transhepatic, or T-tube tracts, or through a surgically created Roux-en-Y jejunal loop, the latter providing a permanent means of repeated biliary access without the need for an internal/external biliary drainage catheter. A number of devices may be directed through the working channel of the scope or used under fluoroscopic guidance to help differentiate benign from malignant lesions. These include the use of biopsy brushes, "clam shell" percutaneous biopsy de-

vices (bioptomes), and electrohydrophilic lithotripsy to fracture stones associated with strictures.

The application of physiological parameters such as the biliary manometric perfusion test (BMPT) helps the multidisciplinary team decide when to remove the biliary drainage catheter. The BMPT will be discussed later in this article and consists of graduated increases in infusion of dilute contrast into the bile ducts. As the biliary system undergoes incremental increases in flow (i.e., "stress" test), pressure measurements are obtained. This test, as well as a clinical trial (i.e., an interval of approximately 14 days in which a biliary drainage catheter is shortened, withdrawn proximal to a stricture or surgical anastomosis, and capped to allow internal drainage across the lesion) assists in the decision as to when to remove the biliary drainage catheter(s). Percutaneous, nonoperative management of the patient with obstructive jaundice requires a dedicated team of professionals. Dialogue between surgeons, endoscopists, interventional radiologists, internal medicine specialists, primary-care physicians, and nurses is required to manage such patients effectively.

---

Russell Morgan Department of Radiology and Radiologic Sciences, Johns Hopkins Medical Institutions, Baltimore, Maryland

Reprint requests: Dr. Venbrux, Department of Radiology, Johns Hopkins Medical Institutions, 600 North Wolfe Street, Balock 545, Baltimore, MD 21287

Copyright ©1996 by Thieme Medical Publishers, Inc., 381 Park Avenue South, New York, NY 10016. All rights reserved.

## ETIOLOGY OF BENIGN BILIARY STRICTURES

Inadvertent trauma during cholecystectomy or common bile duct exploration accounts for approximately 95% of all benign biliary strictures.<sup>1,2</sup> Benign biliary strictures are also a result of inflammatory conditions involving either the bile ducts themselves or the periductal strictures. Such diseases include: chronic pancreatitis, sclerosing cholangitis (either primary or secondary) and necrotizing cholangitis.<sup>3</sup>

## IMAGING OF THE PATIENT WITH OBSTRUCTIVE JAUNDICE

Patients with obstructive jaundice due to benign disease have benefitted from advances in diagnostic imaging. Based on cross-sectional imaging, it is not uncommon to be relatively certain of the cause and the location of bile duct obstruction prior to percutaneous intervention. Detailed anatomy of the intra- and extrahepatic bile ducts may be accomplished by percutaneous and/or endoscopic retrograde cholangiopancreatograms (ERCP). Lacking the potential risks associated with percutaneous transhepatic biliary procedures such as bleeding, ERCP is often the first invasive procedure performed in patients requiring biliary surgery and/or intervention. Endoscopic retrograde cholangiopancreatograms are especially useful in patients with coagulopathies, marked ascites, or in whom intrahepatic lesions (e.g., multiple hepatic cysts, etc) preclude a safe transhepatic approach. Limitations of ERCP in the patient with a benign biliary stricture include: (1) inability to cannulate the biliary system due to surgically altered anatomy (biliary-enteric anastomosis); (2) incomplete filling of intrahepatic bile ducts in patients with high-grade benign strictures with potential risk of sepsis after instrumentation; (3) poor delineation of lengthy or multiple bile duct lesion(s); and (4) technical limitations in treating intrahepatic or hilar lesions from an endoscopic retrograde approach.

If the patient is to be considered an operative candidate for biliary reconstruction (e.g., choledochenterostomy), precise anatomic definition of the intra- and extrahepatic bile ducts is essential in planning the surgical biliary reconstruction. Therefore, percutaneous transhepatic cholangiography (PTC) is the preferred procedure. Percutaneous transhepatic cholangiography accurately depicts the intrahepatic biliary tree, lesion length and lesion number, and defines whether or not the benign biliary disease involves the bifurcation. Should the latter be found, bilateral (i.e., right and left) PTC and biliary drainages may be performed. At the authors' institution, the placement of transhepatic biliary drainage catheters facilitates biliary reconstruction, assisting the sur-

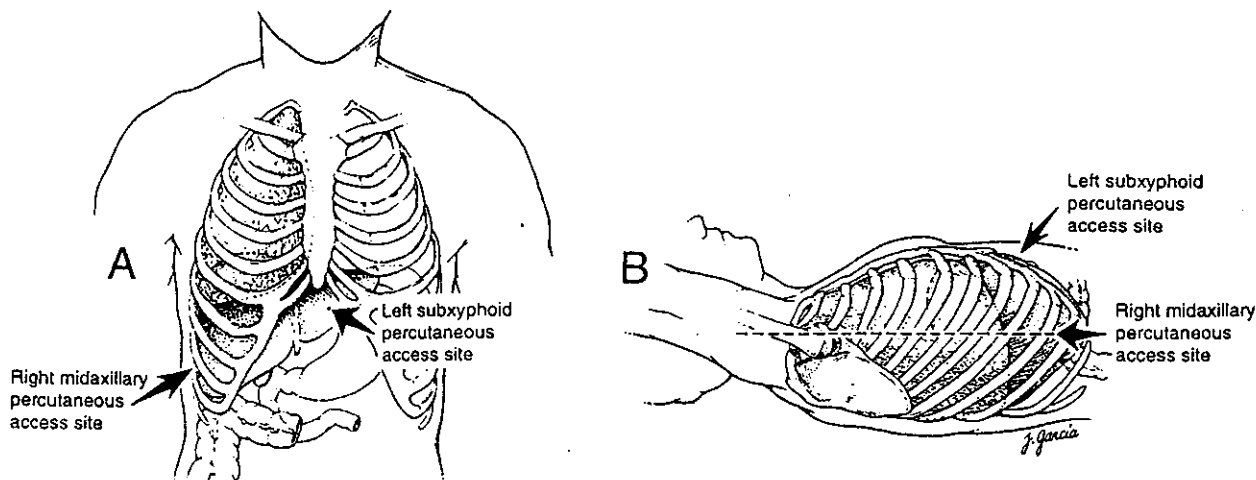
geon in creating the biliary enteric anastomosis. Biliary drainage catheters also provide a means of post-operative stenting.<sup>4</sup> Advances in interventional techniques allow the safe and effective percutaneous use of "skinny needles" for defining biliary anatomy.

Percutaneous transhepatic cholangiography is the first step to a percutaneous biliary drainage (PBD). The only absolute contraindication to PTC/PBD performed as a means of access into the biliary system for the treatment of patients with benign biliary strictures is that of a significant coagulopathy, which cannot be corrected. Percutaneous biliary drainage should be avoided in those patients with diffuse polycystic liver disease, or in patients with hepatic cysts due to parasitic infections (e.g., *Echinococcus*). Occasionally, cross-sectional imaging and percutaneous drainage under computed tomography (CT) guidance may be used to find an appropriate "window" for access into the biliary system in those patients with multiple intrahepatic lesions. Given the advances in interventional techniques, including multidirectional C-arm fluoroscopy, improvements in catheter and guidewire technology, the technical success rate for PBD has improved considerably. Short of complete bile duct transection or clipping during surgery, it is infrequent that obstructions of the biliary system cannot be crossed on the initial drainage procedure with hydrophilic coated catheters and guidewires. The ability to perform an external biliary drainage in patients with biliary sepsis can be lifesaving. The technique for percutaneous transhepatic cholangiography and percutaneous biliary drainage is outlined below.

## TECHNIQUE OF PTC/PBD

Percutaneous transhepatic cholangiography/percutaneous biliary drainage is an invasive procedure. In patients who are not septic, intravenous antibiotics are administered on the day of the procedure and continued for 24 hours after the procedure. Intravenous antibiotics are started immediately upon admission if a patient presents with clinical signs and symptoms of biliary sepsis, cholangitis, etc. A hematocrit, coagulation profile studies, and liver function tests are drawn as part of the authors' routine pre-procedure laboratory analysis.

After the patient has been counselled as to the risks of the procedure, the patient is placed in a supine position. Intravenous sedation and analgesia is administered under an institutional "conscious sedation" protocol and physiological monitoring (i.e., blood pressure, pulse, and oxygen saturation) is recorded frequently. Although some interventional radiologists prefer biliary access from the left sub-



**Figure 1.** Anatomical landmarks for right and left percutaneous transhepatic biliary drainage. *A.* Right midaxillary and left subxyphoid percutaneous access sites. The right-sided approach is low so as to avoid the costophrenic angle; and cephalic enough to avoid percutaneously puncturing the hepatic flexure of the colon. The left subxyphoid approach is dependent upon the size of the left lobe of the liver. A more medial needle placement may be required if the left lobe of the liver is atrophic, as may be seen in patients with chronic left biliary duct obstruction. *B.* Drawing of a supine position. Angulation of the tube image and intensifier during a left-sided approach (i.e., right anterior oblique) reduces radiation to the radiologist's hand and avoids the direct beam. Careful collimation reduces patient exposure.

xiphoid approach, at the authors' institution, a right mid-axillary approach is generally used (Fig. 1A and B).

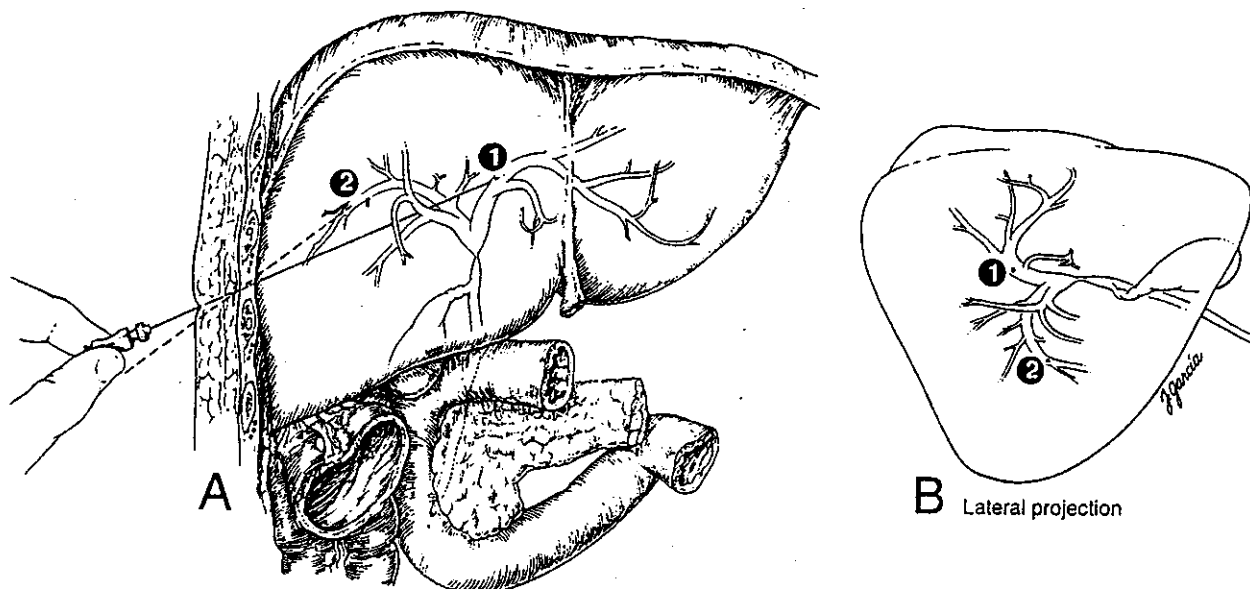
A right mid-axillary approach is performed after anesthetizing the subcutaneous tissues inferior to the level of the costophrenic angle and above the level of the hepatic flexure. The Chiba needle (Cook, Inc., Bloomington, IN) is advanced under fluoroscopic guidance into the liver parallel to the tabletop and directed medially and superiorly (Fig. 1A and B). After removing the stylet, the hub of the Chiba needle is connected to a tubing. The tubing is connected to a syringe containing diluted contrast (1:1 dilution of saline to contrast). As the needle is withdrawn slowly under fluoroscopic guidance, contrast is injected. If the tip of the needle is in a bile duct, contrast is seen to flow away from it. Upon opacification of the biliary anatomy, multiple images are obtained to accurately define anatomy. Should PBD be considered, if a peripheral duct has not been entered, or the point of duct entry is unfavorable for advancement of a guidewire (Fig. 2A and B), a second skinny needle may be used to select a more peripheral duct. Having placed a needle in a more peripheral location (Fig. 2A and B), a "single puncture" ("one-stick") system (i.e., a coaxial system consisting of a small caliber platinum tip steerable guidewire and dilator/stiffening cannula assembly) may be used to secure access. Using this system, the initial small caliber guidewire is exchanged for a larger guidewire (Fig. 3A) and a 8.3F Ring biliary drainage catheter (Cook, Inc., Bloomington, IN) (Fig. 3B) or a similar small caliber biliary drainage catheter may be used to achieve drainage across a bile duct stricture.

At our institution, the rather stiff 8.3F Ring biliary drainage catheter, frequently required for initial placement because of a high-grade obstruction, is usually exchanged and upsized prior to patient discharge for a softer, more comfortable drainage catheter (e.g., Glidex, Meditech, Boston Scientific, Watertown, MA or Cope Loop, Cook, Inc., Bloomington, IN, etc).

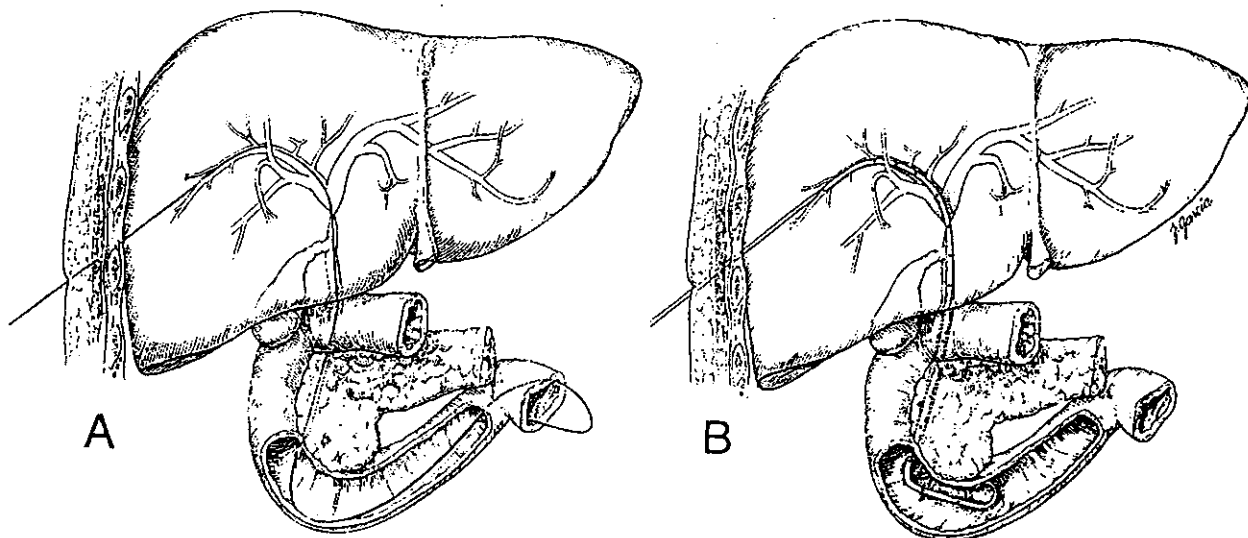
In those patients with a high-grade biliary stricture at the bifurcation isolating the right and left ductal systems, a left PTC/PBD may be required. Anatomical depiction of the left biliary system requires access from a subxyphoid approach (Figs. 1A and B, 2A and B). As part of planning the left PTC/PBD approach, it is important that cross-sectional imaging studies be reviewed to determine whether or not major organs (i.e., transverse colon, etc.) are interposed between the subxyphoid skin entry site and the left lobe of the liver, and/or whether the left lobe is atrophic as may be seen in patients with chronic left biliary obstruction. If the left lobe is atrophic and requires drainage, a subxyphoid approach that is more medial than the standard left-sided subxyphoid percutaneous approach may be required (Fig. 1A and B).

#### PERCUTANEOUS DILATION OF BENIGN BILIARY STRICTURES

Having gained access into the biliary system (Figs. 2 and 3), there is usually a one- to three-day waiting period prior to initiation of balloon dilation.



**Figure 2.** Drawing of percutaneous transhepatic "skinny needle" puncture in a patient with a common hepatic duct biliary stricture. Initial passes with the Chiba needle have resulted in a puncture of the left biliary duct (Site 1). Although adequate for defining biliary anatomy, the angle is not appropriate for percutaneous drainage. A second needle may then be used to achieve a favorable access for a percutaneous transhepatic biliary drainage. (Site 2) The second needle path is depicted with dotted lines. A. Note the placement of the percutaneous transhepatic "skinny needle" is just cephalic to the lower rib to avoid the intercostal neurovascular structure. B. Drawing of the puncture sites 1 and 2 in the lateral projection.



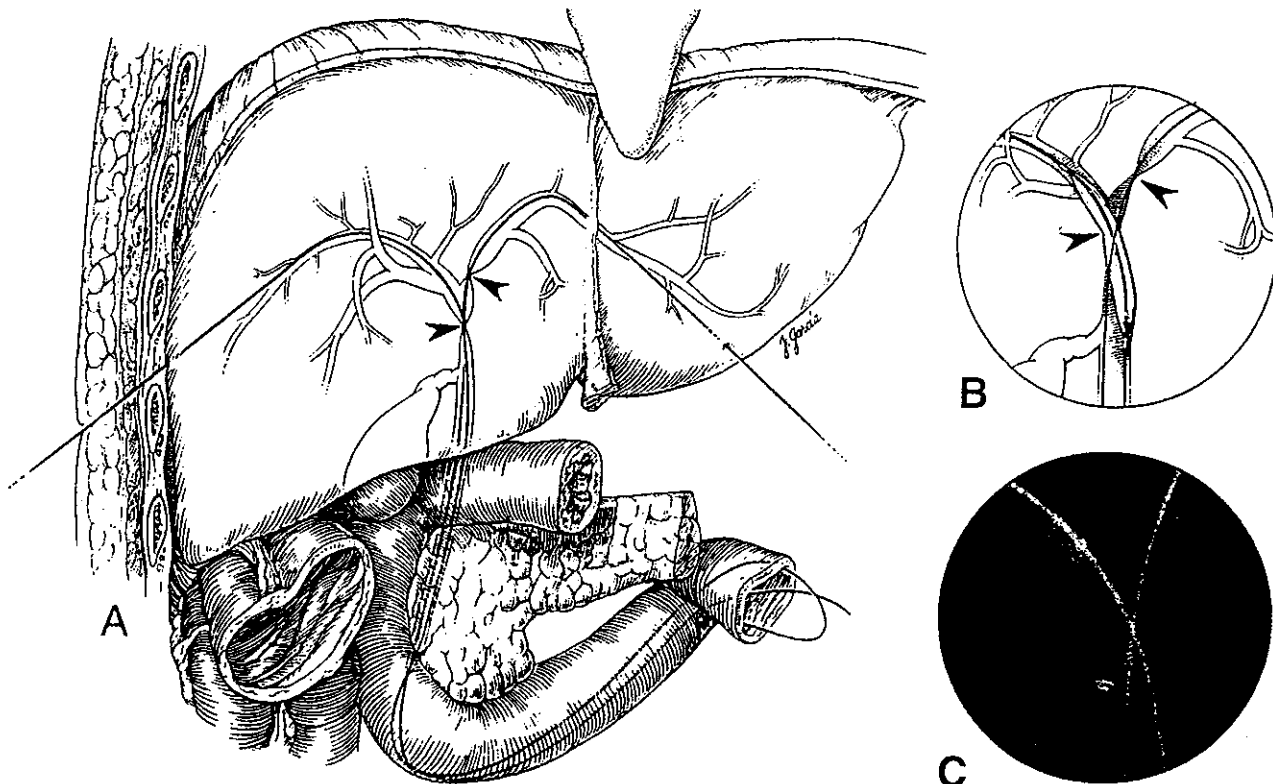
**Figure 3.** Drawings of patient during percutaneous transhepatic biliary drainage for extrahepatic (common hepatic) biliary stricture. A. A stiff guidewire replaces the 0.018-inch in diameter steerable guidewire to place the biliary drainage catheter. Note the guidewire crossing the common hepatic duct stricture. B. An 8.3F Ring biliary drainage catheter (Cook, Inc., Bloomington, IN) has been advanced through the stricture to complete the internal/external biliary drainage. The rather stiff biliary drainage catheter, often required for the initial drainage, may be exchanged for a softer more comfortable catheter. Once tract maturation occurs, the biliary drainage catheter may be removed over a guidewire and the patient's biliary stricture balloon dilated and stented with a larger caliber biliary drainage catheter.

A stiff guidewire is directed down the indwelling biliary drainage catheter. The biliary drainage catheter is removed and an angioplasty balloon is advanced over the guidewire under fluoroscopic guidance to the region of stricture. In general, we begin with an 8- to 10-mm diameter balloon. This, of course, depends on the size of the duct. If there is no waist seen during balloon dilation at the site of biliary stricture, a balloon with a larger diameter is used and the dilation repeated. Figure 4A-C summarize a balloon dilation procedure in a patient with bilateral benign biliary strictures. Note the bilateral percutaneous accesses.

Once dilated, the stricture is stented with a large internal/external biliary drainage catheter for several months. In general, an attempt is made to upsize the biliary drainage catheter from 8.3F to 16F. This is frequently a stepwise process; cholangiography and tube upsizing being performed as outpatient procedures. We prefer the large silastic stents (Heyer-Schulte silastic stents, Bentec, Sacramento, CA). The duration of stenting is controversial. At the authors' institution, patients with a biliary stricture not requir-

ing surgical biliary reconstruction are stented for a minimum of 3 months after balloon dilation. Those patients who have undergone repeat biliary surgical reconstruction with creation of Roux-en-Y hepaticojejunostomies and who develop anastomotic stricture at a later date, undergo balloon dilations followed by long-term bilateral stenting (e.g., 6-12 months).

In those patients with benign biliary disease associated with biliary tract stone disease (i.e., extrahepatic choledocholithiasis and hepatolithiasis), the patient must undergo endoscopic and/or percutaneous therapy to remove stones prior to balloon dilation of the stricture(s). For those patients with extrahepatic (i.e., common bile duct) stones, endoscopic treatment with sphincterotomy is the preferred method because the patient is not subject to the risks of percutaneous transhepatic biliary drainage.<sup>4</sup> In those patients who have had an operatively placed T-tube, tract maturation followed by fluoroscopic<sup>5,6</sup> or endoscopic<sup>7-9</sup> biliary interventions with stone removal and stricture dilation has proven valuable with minimal patient morbidity.



**Figure 4.** Drawing and spot film radiograph of a patient with left main bile duct and common hepatic duct strictures. *A.* Bilateral percutaneous access has been performed and guidewires are in place. The biliary strictures (arrowheads) are noted on the drawing. *B.* The common hepatic duct stricture has been dilated with a balloon advanced over the guidewire. The sites of strictures are indicated with arrowheads. *C.* Spot film image obtained from a patient with a similar stricture depicted in the drawings; however, in this patient, surgical clips indicate prior cholecystectomy. This patient developed strictures after gallbladder removal.

If transhepatic access is available and intrahepatic stones are present, the tract may be upsized and percutaneous transhepatic biliary endoscopy may be effectively used to remove stones and to treat the benign strictures under direct vision.<sup>7-9</sup> In those patients with primary hepatolithiasis and extensive stone burden with multiple biliary strictures, biliary reconstruction with creation of a Roux-en-Y hepatico-jejunostomy after preoperative PTC/PBD followed by combined transhepatic percutaneous cholangioscopy (i.e., choledochoscopy) with stone fragmentation and cholangioplasty helps clear the biliary tree of stone burden. This is frequently a stepwise procedure. The combined approach has resulted in favorable outcomes in a treatment group of 54 patients reported in the surgical literature from The Johns Hopkins Hospital. At a mean follow-up of 60 months, 87% were alive and symptom free. Ninety-four percent of patients remained stone free at the end of the follow up. In 10 patients, percutaneous management was the only therapy when recurrent disease was discovered. Complete stone clearance was achieved in the 10 patients with an average of 1.8 choledochoscopies and 0.5 choledochoplasties per patient. Complications in the 10 patients treated using percutaneous techniques included 1 patient with self-limiting cholangitis treated with antibiotics.<sup>10</sup> The majority of trans T-tube or transhepatic biliary endoscopic procedures are performed on an outpatient basis with only mild intravenous sedation required.<sup>7-9</sup>

#### PERCUTANEOUS MANAGEMENT OF IATROGENIC BILIARY STRICTURES

Patients with suspected bile duct injury may be treated with percutaneous biliary drainage to divert bile flow away from a leak. Prior to percutaneous drainage however, radionuclide imaging may be used to evaluate patients with suspected biliary ductal injury (e.g., in patients who have undergone laparoscopic or open cholecystectomy in whom a leak is later clinically suspected). In an article by Gillman *et al.*,<sup>11</sup> radionuclide imaging was applied and found to be easy, noninvasive, and accurate in documenting bile leakage in three patients who underwent laparoscopic cholecystectomy and postoperatively were suspected of having bile leaks.

In an article by Trerotola *et al.*,<sup>12</sup> 13 patients with biliary complications following laparoscopic cholecystectomy were evaluated with Radiological studies and interventional procedures. The authors found that strictures resulting from laparoscopic cholecystectomy appeared to be markedly resistant to percutaneous management. Surgical repair was the usual course; however, interventional procedures before and after surgery were important in the management

of such patients. In this article, the most commonly performed interventional procedure was PTC/PBD. In five patients with primary biliary strictures after laparoscopic cholecystectomy who underwent biliary drainage before operative repair, attempts to cross the lesion at the initial biliary drainage were unsuccessful in all five.<sup>12</sup> Of additional importance, in contrast to primary biliary strictures resulting from laparoscopic cholecystectomy injury, strictures due to primary *repair* of laparoscopic cholecystectomy injuries (i.e., biliary-enteric anastomotic strictures, etc) were amendable to percutaneous management.

Strictures or obstructions due to conventional cholecystectomy are somewhat more amenable to percutaneous management. As reported by vanSonnenberg *et al.*,<sup>13</sup> 12 of 24 strictures or obstructions after conventional (i.e., "open") cholecystectomy were amendable to percutaneous treatment using interventional techniques.

#### ROLE OF BILIARY ENDOPROSTHESES IN THE TREATMENT OF BENIGN BILIARY STRICTURES

Biliary endoprosthesis, either metal or plastic, placed endoscopically or transhepatically should, in general, be avoided in patients with benign biliary strictures. Experience to date has shown poor long-term results with high occlusion rates. Biliary endoprosthesis should be reserved for those patients who have underlying malignancies and limited life expectancy or only as a last resort in those patients who have no options available (i.e., are extremely poor surgical candidates). In such patients, the use of biliary endoprosthesis may be considered. In those patients with extrahepatic strictures and plastic endoprosthesis, follow-up endoscopy and exchange at approximately 6-month intervals is necessary because of the risk of endoprosthesis occlusion and development of sepsis. In general, metallic stents should not be used for benign strictures because of the incorporation of the metallic struts into the bile duct epithelium. Currently available metallic stents cannot be removed endoscopically or percutaneously. Should the patient later be forced to undergo a biliary surgical reconstruction, a greater length of the bile duct may need to be resected as a result of the metallic implant. In limited circumstances, patients who have undergone hepatic transplantation and have a focal stricture at the choledochocholedochostomy anastomosis may benefit from a short segment metallic stent. However, as emphasized, metallic stents for treatment of patients with benign biliary strictures should be avoided. Stent migration, dislodgment, and obstruction are a few of the problems associated with biliary endoprosthesis.

## BILIARY DRAINAGE CATHETER MANAGEMENT AND RESULTS OF INTERVENTIONS

At the authors' institution, once balloon dilation of benign biliary strictures has been achieved, internal-external stents are the preferred method of maintaining biliary access. This allows for follow-up cholangiography and, if necessary, repeat stricture dilation or intervention. Patients undergo biliary catheter exchanges at approximately 3-month intervals on an outpatient basis. Intravenous antibiotics in a single dose are given to those patients who are asymptomatic, requiring routine tube changes. If a patient is septic at the time of presentation, intravenous antibiotics are begun immediately, the biliary drainage catheter is exchanged, and the patient is admitted for continued intravenous antibiotic therapy.

The decision when to remove the biliary drainage catheter in a patient who has undergone treatment of benign biliary strictures is based on clinical and laboratory parameters and on biliary flow dynamics. As emphasized, the duration of stenting is controversial. If, for example, a focal benign biliary stricture has been stented for a minimum of 3 months, a decision is made as to when to remove the tube. However, prior to losing transhepatic access, an over-the-wire cholangiogram is performed by pulling the biliary drainage catheter back over a guidewire. If the site of stented stricture looks patent based on an injection of contrast through the tube using a "Y-adaptor," a decision is made to initiate a "clinical trial." For this, a shortened biliary drainage catheter is reintroduced over the guidewire (same caliber) but the tip is placed above the biliary stricture. Usually multiple sideholes are cut off to achieve the shortened tube. This functions to maintain percutaneous access and to allow bile to flow across the nonstented, previously dilated, stricture. The tube is capped for 1 to 2 weeks. Any signs or symptoms of cholangitis, right upper quadrant pain, fever, or jaundice indicates a failure of the "clinical trial." Comparison of laboratory data (e.g., liver function tests, etc) before and after clinical trial is also made. A follow-up cholangiogram is performed. If the patient has failed the "clinical trial," percutaneous access has been maintained. The stricture is redilated and restented.

If the patient remains asymptomatic during the "clinical trial," and there is documented evidence of flow across the stricture on follow-up cholangiography, a biliary manometric perfusion test is performed. Stepwise infusions of dilute contrast are infused at each strictured site via the shortened percutaneously placed tube. Biliary pressures less than 20 cm of H<sub>2</sub>O are considered "normal." In patients with successful balloon dilation, an asymptomatic "clinical trial," and normal pressures during the biliary manometric

perfusion test, a positive predicted value for biliary duct patency at 1 year approaches 90%.<sup>14</sup> Patients are followed carefully with follow-up liver function tests and at periodic intervals after tube removal.

In the medical literature, published data for results of percutaneous balloon dilation and stenting indicate long-term patency of 55 to 76% with follow-up periods of 5 and 3 years, respectively. However, most of the data is retrospective in nature.<sup>10</sup> Long-term patency rates at our institution for surgical repair of similar lesions are 89% at 72-months follow-up. The initial reports of percutaneous balloon dilation showed significant complications including hemobilia. This, however, was primarily related to transhepatic access. A more recent multicenter review of cases revealed a 5% complication rate, primarily due to cholangitis with no hemobilia or significant mortality.<sup>4</sup>

In patients with sclerosing cholangitis, a combined approach seems to be the most efficacious manner in handling patients with multiple strictures. Patients with extrahepatic biliary strictures may benefit from endoscopic dilation. Operative resection of dominant strictures that fail to respond to endoscopic dilation or in those patients with strictures at the bifurcation is advocated for most symptomatic patients. Percutaneous transhepatic cholangiography is useful in defining the anatomy, whereas PBD may be useful in setting the stage for operative biliary reconstruction. However, the purely nonoperative management of patients with sclerosing cholangitis remains controversial and long-term results are limited. Ultimately, most patients require hepatic transplantation; however, nonoperative treatment of specific patients with percutaneous dilation of dominant intrahepatic strictures may minimize bouts of cholangitis and prolong liver function.<sup>10</sup>

## CONCLUSION

The radiologist plays a key role in the nonsurgical management of patients with benign biliary strictures. Stenting of benign biliary strictures frequently requires a long course of biliary duct intubation (e.g., months) thus, internal/external biliary drainage catheters (stents) should be used to maintain percutaneous access into the bile ducts. Such stents require periodic exchanges to prevent sepsis due to occlusion of the lumen by bacteria and biliary debris. Biliary endoprostheses should not be used in the treatment of patients with benign biliary strictures unless other options have failed. The decision to remove a biliary drainage catheter is based on the nature of the biliary stricture, the institution of the "clinical trial," and/or successful completion of a biliary manometric perfusion test. The latter is particularly helpful in those

patients with chronic abdominal pain. In such instances, the pain experienced by such patients during a clinical trial may be unrelated to the bile duct obstruction at the site of a treated biliary stricture. In such instances, successful completion of both the clinical trial (i.e., no elevation in liver function tests, bilirubin, episodes of cholangitis, etc) and a normal biliary manometric perfusion test reassures the physician that the tube may be safely removed.

Patients with iatrogenic benign biliary strictures due to laparoscopic cholecystectomy injury frequently fail percutaneous therapy. Percutaneous external drainage with diversion of bile to reduce sepsis aids a surgeon in the preoperative management of such a patient. In contrast, percutaneous management of biliary enteric anastomotic strictures generally respond well. More recently, the application of fiber optics as an adjunct to biliary interventions has given the radiologist the ability to treat stone disease with electrohydrophilic lithotripsy under direct vision, to biopsy suspicious lesions, and to assist in the crossing of eccentric high-grade strictures, which may have otherwise failed treatment by fluoroscopic means. This ultimately reduces the radiation exposure to the patient, interventional radiologist, and personnel in the room.

Improvements in techniques of percutaneous transhepatic cholangiography, percutaneous biliary drainage, and adjunctive biliary interventions provide the radiologist with ready access into the biliary system to assist in the multidisciplinary management of patients with complex disease. This "team approach" includes surgeons, radiologists, gastroenterologists, and primary-care physicians. It is hoped that the above information summarizes the nonsurgical therapeutic options available in the management of patients with benign biliary strictures.

## REFERENCES

1. Lillemoe KD, Pitt HA, Cameron JL: Postoperative bile duct strictures. *Surg Clin North Am* 1990;1355-1380
2. Braasch WJ, Warren KW, Blevens PK: Progress in biliary stricture repair. *Am J Surg* 1975;129:34-37
3. Lammer J, Deu E: Percutaneous management of benign biliary strictures. In Kadir S (ed): *Current Practice of Interventional Radiology*. Philadelphia: Decker Inc., 1991, pp. 550-553
4. Osterman FA Jr, Venbrux AC: Obstructive jaundice: percutaneous transhepatic interventions. In: Cameron JL (ed): *Current Surgical Therapy*, 5th ed. St. Louis: Mosby-Year Book, Inc., 1995, pp. 394-399
5. Burhenne HJ: Nonoperative retained biliary tract stone extraction. A new roentgenologic technique. *Am J Roentgenol* 1973;117:388-399
6. Burhenne HJ: The technique of biliary duct stone extraction. *Radiology* 1974;113:567-572
7. Picus D, Wyman PJ, Marx MV: Role of percutaneous intracorporeal electrohydraulic lithotripsy in the treatment of biliary tract calculi. *Radiology* 1989;170:989-993
8. Venbrux AC, Robbins KV, Savader SJ, et al.: Endoscopy as an adjuvant to biliary radiology intervention. *Radiology* 1991;180:353-361
9. Venbrux AC, Osterman FA Jr: Percutaneous biliary endoscopy. In: LaBerge JM, Venbrux AC (eds): *Biliary Interventions. SCVIR Syllabus*. Reston, VA: SCVIR, 1995, pp. 246-258
10. Lillemoe KD, Pitt HA, Cameron JL: Current management of benign bile duct strictures. *Adv Surg* 1992;25:119-174
11. Gillman R, Alexander MS, Zucker KA, Bailey RW: The use of radionuclide imaging in the evaluation of suspected biliary damage during laparoscopic cholecystectomy. *Gastrointest Radiol* 1991;16:201-204
12. Trerotola SO, Savader SJ, Lund GB, et al.: Biliary tract complications following laparoscopic cholecystectomy: imaging and intervention. *Radiology* 1992;184:195-200
13. vanSonnenberg E, Casola G, Wittich GR, et al.: The role of interventional radiology for complication of cholecystectomy. *Surgery* 1990;107:632-638
14. Savader SJ, Cameron JL, Pitt HA, et al.: Biliary manometry versus clinical trial: value as predictors of success after treatment of biliary tract strictures. *JVIR* 1994;5:757-763

The authors thank Debbie Offenbacher and Kay Marseglia for the preparation of this manuscript.