

Gastroschisis: A Simple Technique for Staged Silo Closure

By James D. Fischer, Karen Chun, Donald C. Moores, and H. Gibbs Andrews
Loma Linda, California

● In conjunction with the Neonatology Department at Loma Linda University Children's Hospital, a new protocol has evolved for the management of infants with gastroschisis, which obviates both risks associated with primary and staged silo closure. After stabilization of the infant in the neonatal intensive care unit, under sterile conditions, a 5- or 7-cm SILASTIC® silo with a spring-loaded ring is placed over the exposed viscera, under the fascial defect. No sutures are required. A fentanyl drip is given, and the bowel is gradually reduced over the next few days. The transparent material of the silo allows for continuous monitoring of the condition of the bowel. Second-stage closure in the operating room is performed using a purse-string suture in the fascia to create a pseudumbilicus. From October 1992 to April 1994 the authors managed 10 infants using this protocol. The results are compared with those of infants with gastroschisis treated at the same institution between August 1982 and June 1993. Outcome parameters to be compared include time until closure, time on ventilation, days of total parenteral nutrition, time until start of oral feeding, time until toleration of full-volume oral feeding, and time until discharge. The authors conclude that silo closure in the neonatal intensive care unit is simple, quick, and effective. It eliminates multiple trips to the operating room, allows the natural accommodation of the bowel into the abdominal cavity with little edema and minimal vascular compromise, and has become the authors' treatment of choice for infants with gastroschisis.

Copyright © 1995 by W.B. Saunders Company

INDEX WORDS: Gastroschisis, silo closure.

THE APPROACH to treatment of babies with gastroschisis remains controversial. Although all would agree that early closure without respiratory, gastrointestinal, or vascular compromise is the ideal, the method of accomplishing this is still debatable.¹⁻⁵ A new protocol has evolved at our institution, which involves early insertion of a silo in the neonatal unit, with planned secondary closure of the defect after the baby's condition has stabilized and bowel edema has resolved.

MATERIALS AND METHODS

From October 1992 to April 1994, 10 babies with gastroschisis admitted to the neonatal unit at Loma Linda Children's Hospital were treated according to the protocol. After transport to the neonatal intensive care unit (NICU), appropriate lines are established, using the umbilicus if necessary. A 5- or 7-cm SILASTIC® silo (Dow Corning, Midland, MI) with a spring-loaded ring (Ben Tec, Sacramento, CA) (Figs 1 and 2) is placed over the exposed viscera, under the fascial defect. This is performed under sterile conditions in the NICU, with patient sedation. No sutures are required. The silo is closed progressively with umbilical tape over the next few days (Fig 3). Mild patient sedation is used. The baby is monitored at all times, and the tapes can be removed quickly if necessary. The transparent material of the silo allows continuous




Fig 1. SILASTIC® silo with spring-loaded ring.

monitoring of the condition of the bowel (Fig 4). When appropriate, usually between 2 and 7 days, the silo is removed and the defect closed with a purse-string suture to create a pseudumbilicus. This second stage initially was performed in the operating room, but recently we have performed it at the bedside in the NICU, with sedation for the baby (Fig 5).

RESULTS

From October 1992 to April 1994 we managed 10 infants using this method. The outcome parameters studied for all groups were time until completion of closure, time on ventilator, days of total parenteral nutrition (TPN), time until start of oral feeding, time

From the Division of Pediatric Surgery, Loma Linda University Children's Hospital, Loma Linda, CA.

Presented at the 26th Annual Meeting of the Canadian Association of Paediatric Surgeons, Toronto, Ontario, September 19-21, 1994.

Address reprint requests to James D. Fischer, MD, Division of Pediatric Surgery, Loma Linda University Children's Hospital, 11234 Anderson St, Room 2416, Loma Linda, CA 92354.

*Copyright © 1995 by W.B. Saunders Company
0022-3468/95/3008-0015\$03.00/0*

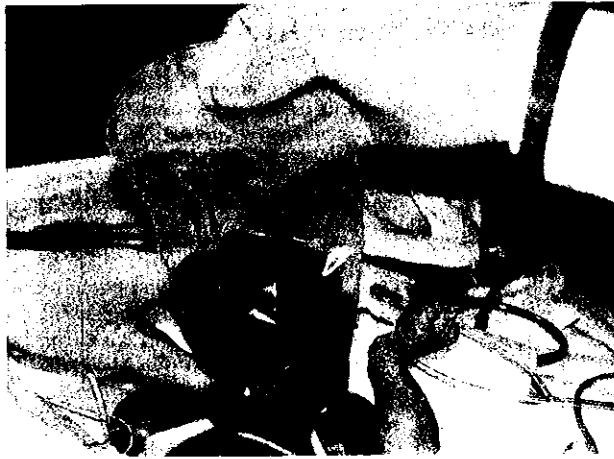

Fig 2. Gastrochisis before silo insertion.

until toleration of full-volume oral feeding, and time until discharge. There was no significant difference in parameters except with respect to time until closure in the primary closure group (Table 1).

There were no cases of necrotizing enterocolitis in the children treated by staged silo closure. Three children with staged silo closure had localized cellulitis that resolved with antibiotics and wound care.

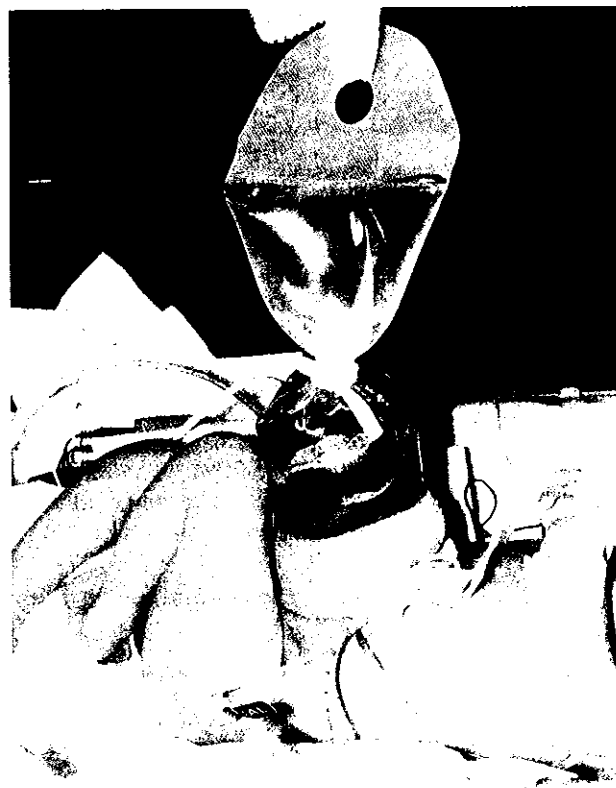

Fig 3. Gastrochisis with silo in place.

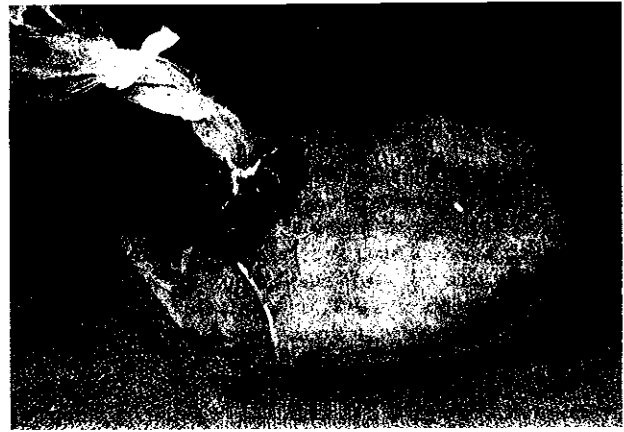

Fig 4. Staged reduction of transparent silo.

None of the 10 babies treated with staged silo closure had sepsis.

DISCUSSION

Although the goal of treatment for the baby with gastrochisis is closure of the defect as soon as safely possible, there is still controversy regarding the timing of the closure, ie, primary versus staged closure.³⁻⁶ Primary closure is done with one trip to the operating room, and the risk of sepsis would appear to be lower. However, primary closure carries the risk of compromising the vascular supply to the bowel, as well as the fact that in some cases the peritoneal cavity will just not accommodate the displaced bowel.^{2,7}

Some surgeons advocate using intraoperative measurements of intragastric and central venous pressure to determine the feasibility of primary closure.⁸ However, this can be subjective and has not gained widespread acceptance. Staged closure can alleviate some of the problems of bowel compromise but entails a trip to the operating room and a sutured silo, which can result in disruption or sepsis.⁹



Fig 5. Final result after fascial closure.

Table 1. Outcome Parameters

	Time Until Completion of Closure (d)	Ventilator Days	TPN Days	Time Until Start of Oral Feeding (d)	Time Until Tolerant of Full-Volume Oral Feeding (d)	Time Until Discharge (d)
Primary (25)	1	3-15	5-46	7-22	10-30	11-38
Staged (52)	3-9	5-17	9-42	9-23	12-30	14-35
Silo staged (10)	2-8	2-10	8-44	9-18	11-25	12-37

Necrotizing enterocolitis is a real concern in children with gastroschisis who have had closure,^{10,11} and although the etiology remains obscure, the effect of increased intraabdominal pressure with edematous bowel placed under tension cannot be overlooked.

In an attempt to alleviate the problems of primary closure and reduce the difficulties encountered with staged closure, we have developed a method of staged

silo closure of gastroschisis that permits early coverage of the defect with no need for an operating room, and allows reduction to occur under direct vision and at a rate appropriate for each case, followed by elective closure of the final defect. Therefore, for children with gastroschisis, we advocate staged silo closure as the method of choice for all but very small defects.

REFERENCES

1. Di Lorenzo M, Yazbeck S, Ducharme J-C: Gastroschisis: A 15-year experience. *J Pediatr Surg* 22:710-712, 1987
2. Bryant MS, Tepas JJ III, Mollitt DL, et al: The effect of initial operative repair on the recovery of intestinal function in gastroschisis. *Ann Surg* 55:209-211, 1989
3. Canty TG, Collins DL: Primary fascial closure in infants with gastroschisis and omphalocele: A superior approach. *J Pediatr Surg* 18:707-712, 1983
4. Ein SH, Rubin SZ: Gastroschisis: Primary closure or silo pouch. *J Pediatr Surg* 4:549-552, 1980
5. Swartz KR, Harrison MW, Campbell JR, et al: Selective management of gastroschisis. *Ann Surg* 203:214-218, 1986
6. Swift RI, Singh MP, Ziderman DA, et al: A new regime in the management of gastroschisis. *J Pediatr Surg* 27:61-63, 1992
7. Ein SH, Superina R, Bagwell C, et al: Ischemic bowel after primary closure for gastroschisis. *J Pediatr Surg* 23:728-730, 1988
8. Yaster M, Scherer TL, Stone MM, et al: Prediction of successful primary closure of congenital abdominal wall defects using intraoperative measurements. *J Pediatr Surg* 24:1217-1220, 1989
9. Sawin R, Glick P, Schaller R, et al: Gastroschisis wringer clamp: A safe simplified method for delayed primary closure. *J Pediatr Surg* 27:1346-1348, 1992
10. Oldham KT: Post-operative necrotizing enterocolitis in 10 of 54 infants with gastroschisis. *J Pediatr Surg* 24:1214, 1989
11. Oldham KT, Coran AG, Drongowski RA, et al: The development of necrotizing enterocolitis following repair of gastroschisis: A surprisingly high incidence. *J Pediatr Surg* 23:945-949, 1988